

Utilisation of MCM2 staining in assessment of pOLT liver biopsies with HCV infection.

Dr S E Davies
Addenbrookes Hospital
Cambridge

HCV infection post transplant

- Universal but Unusual c.f. native
- Spectrum of changes in the graft; mild and stable or slowly progressive; rapidly progressive either to cirrhosis or cholestatic form (<10%)
- 10-30% cirrhosis at 5 years
- Apparent increase in rate of fibrosis
- Although short term survival for HCV negative and positive similar now decreased patient and graft survival
- Time from cirrhosis to decompensation ↓

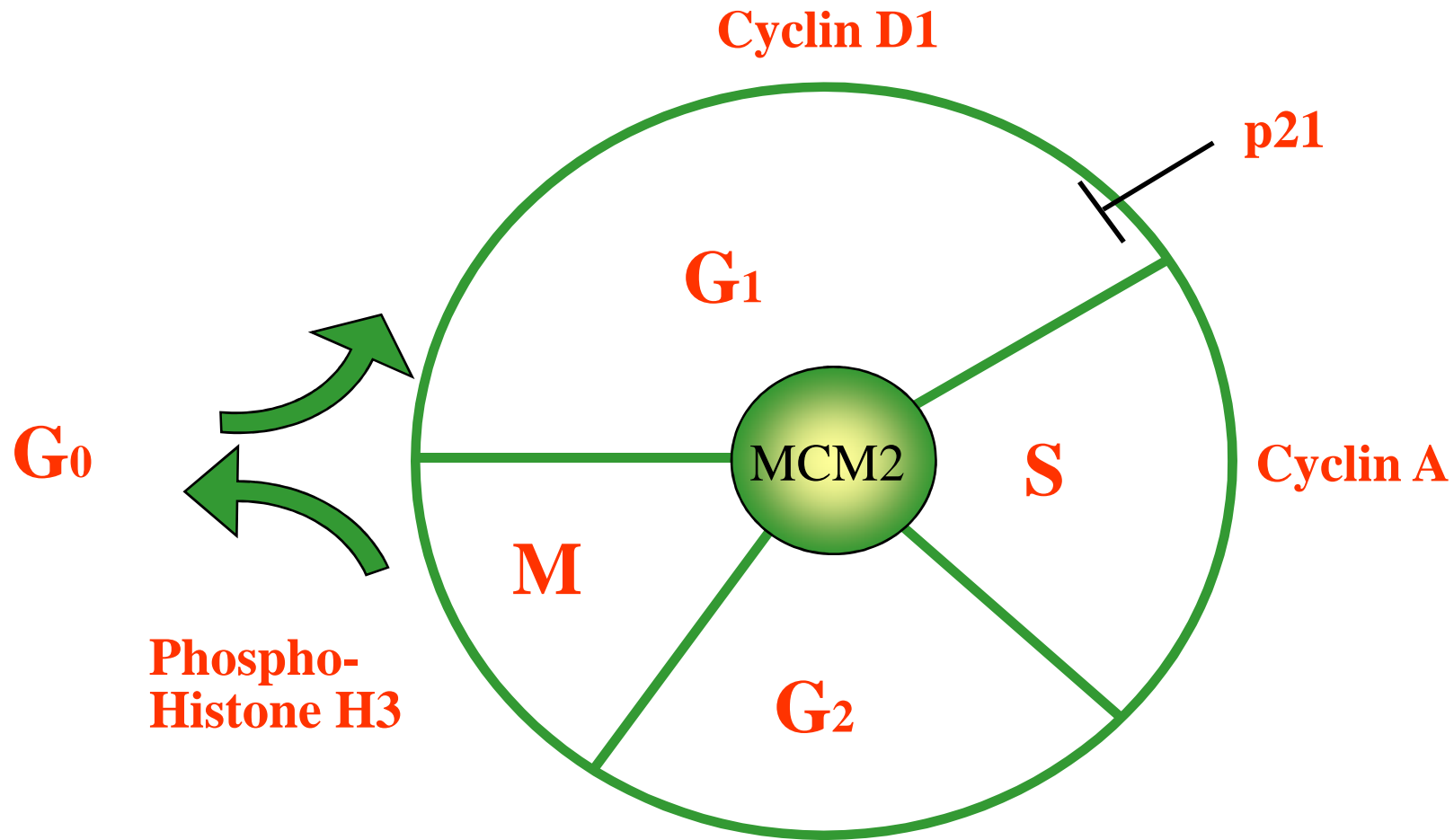
Factors implicated in rapid progression

- Donor age
 - Viral load pre-transplant
 - Warm ischaemia time
 - Immunosuppression
-
- Number of episodes of rejection- treated
 - Severity of hepatitis at recurrence
 - Degree of fibrosis at 1 year

Cell Cycle Markers -Minichromosome maintenance proteins –MCM2

- Best known of M2-7 – family, preserved in eukaryotes cells Tye, Annu Rev Biochem 99
- Present in G1 phase – necessary for gene replication in S phase
- Down regulated in differentiation and quiescence; usually in restrictive proliferative compartments
- Antibodies raised against MCM2 protein; formalin fixed paraffin embedded tissues Freeman Clin Cancer Res 99

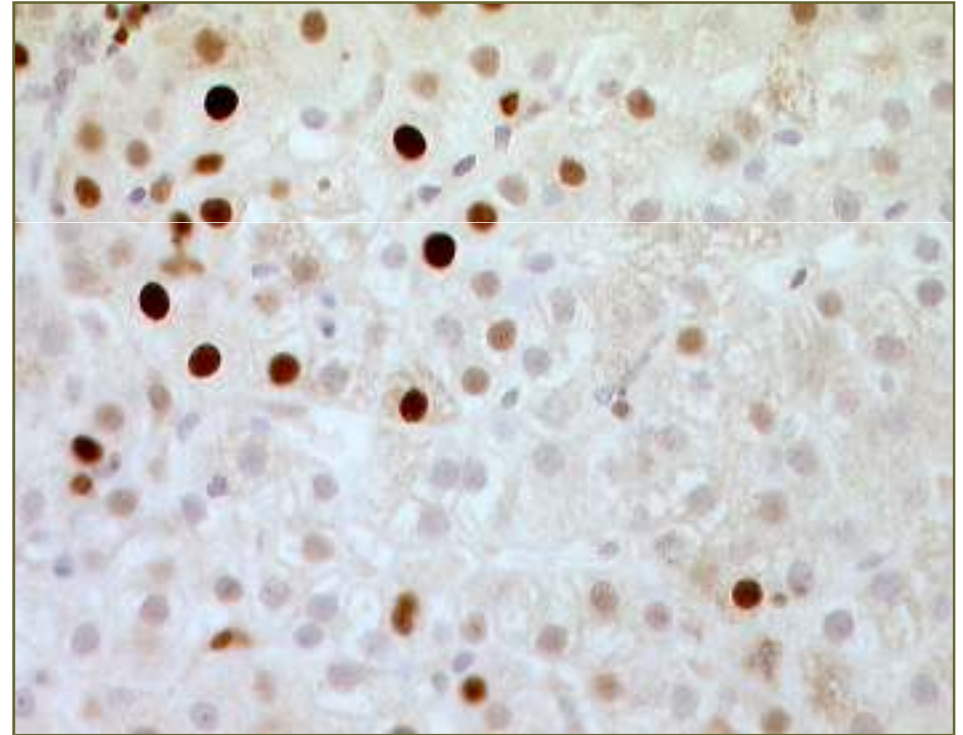
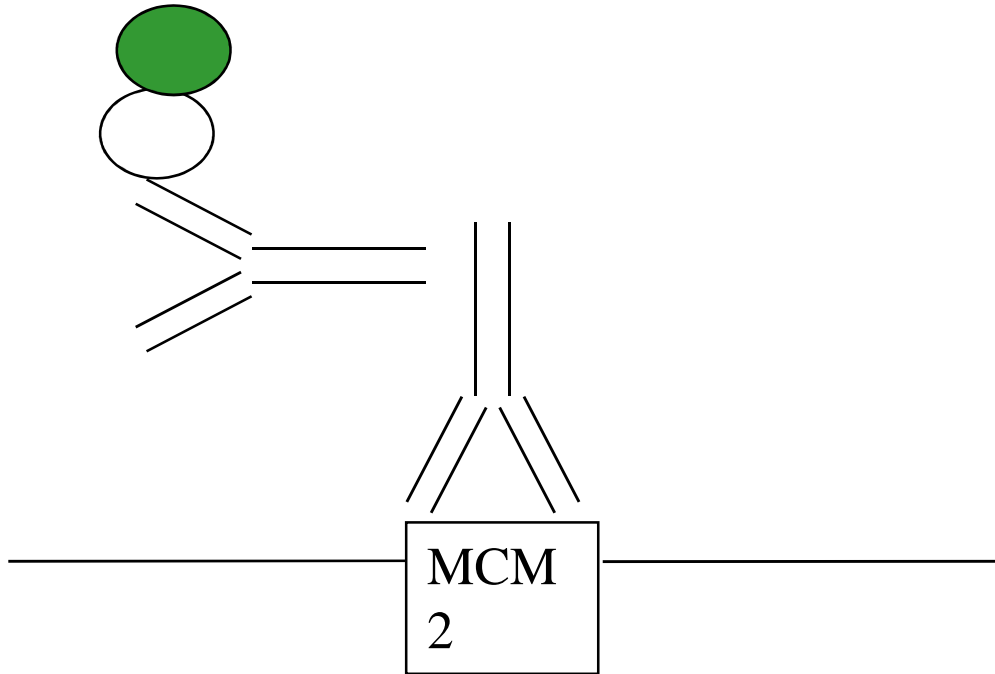
Minichromosome maintenance protein-2, MCM2



Marks entry into cell cycle

Cyclin B1

Methodology 1

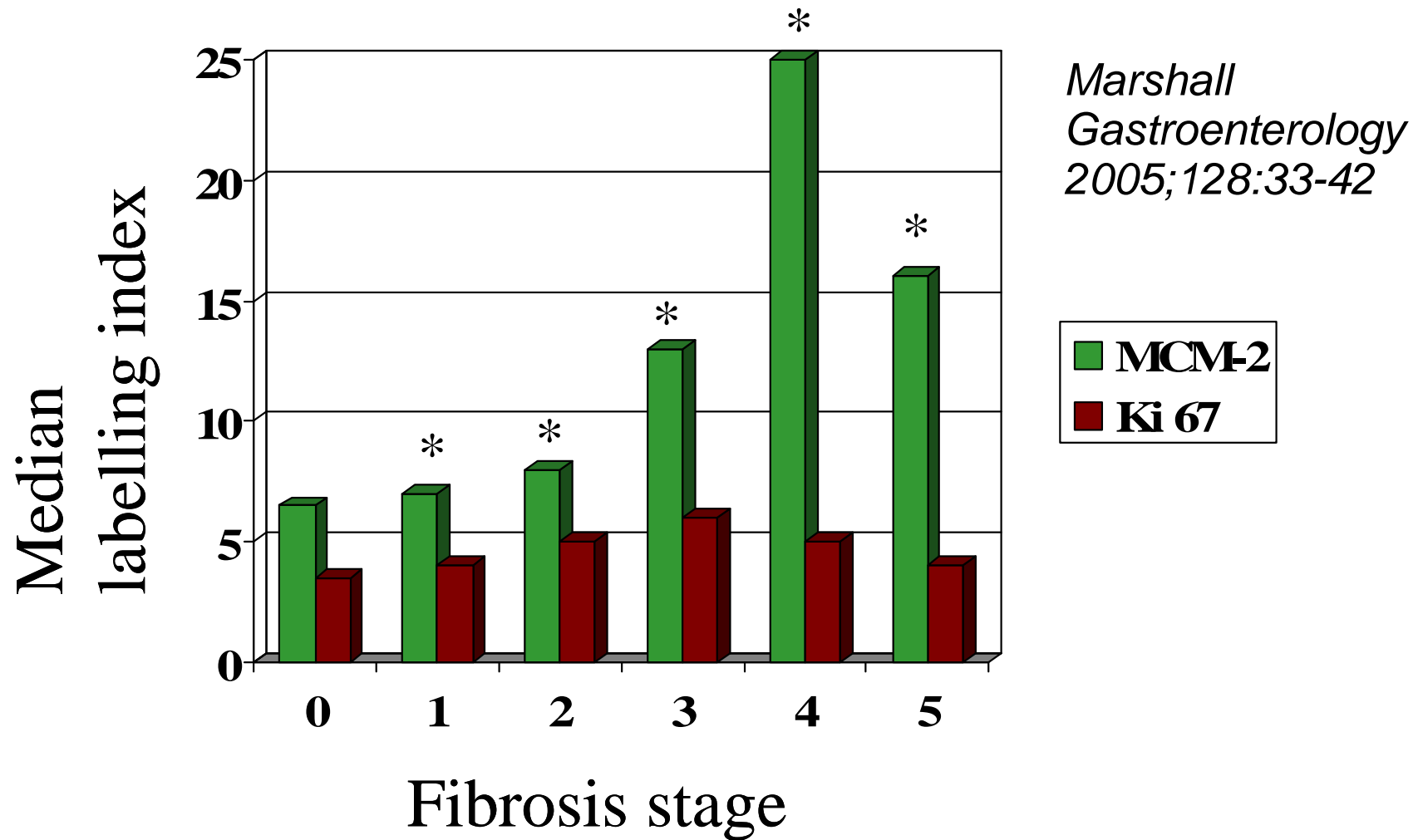


- Positive and negative cells counted
- Highest and 4 random high power fields counted – to give percentage
- Highest and predominant values for MCM2

HCV Infection

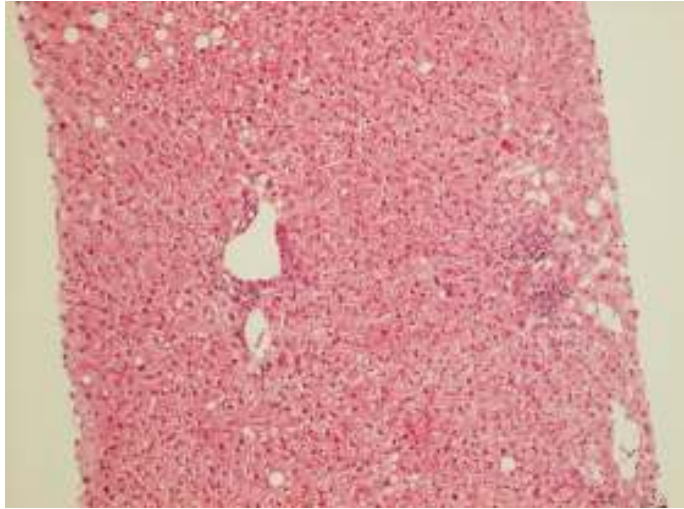
- In non-transplant HCV chronic infection, MCM2 expression was analysed in 87 patients
- Randomly chosen fields
- Compared with Ki67
- Compared with Stage of disease i.e. fibrosis

MCM-2 expression in chronic HCV – according to Stage of fibrosis (not Ishak)

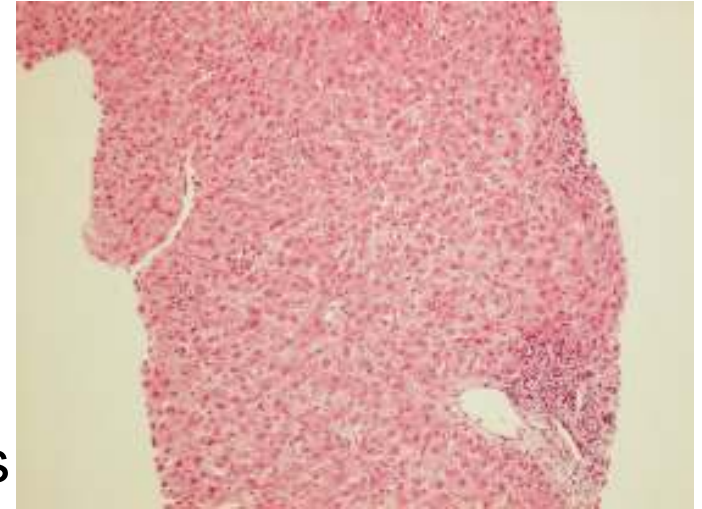


**p<0.01*

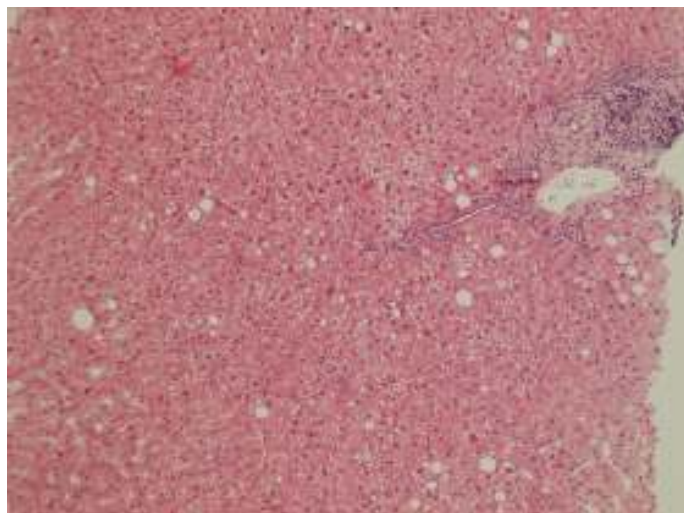
Neither of these had ACR treated, donors > 60yrs,
nor different immunosuppression....



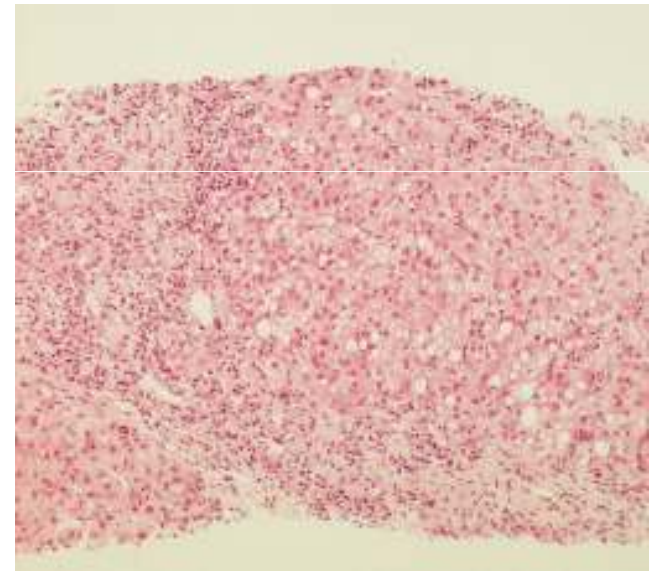
8
months



5
months



5 years



20
months

Case 1

Case 2

Post Transplant HCV

- 1990-1999 all HCV positive recipients 1st graft
n=44
- Yearly biopsies + clinically indicated
- Exclusion
 - < 5yrs follow up n=8
 - Insufficient tissue n=11
 - Chronic rejection n=2
 - Biliary disease n=1
 - Autoimmune n=1

n=23
- Ishak score + steatosis + standard IHC

Grouped into 3

- Fibrosis stage at last biopsy divided by years post transplant = number of stages per year
- No/Minimal Progression
 - \leq stage 2 at 5yrs n=5
- Rapid Progression
 - Stage 6 by 2-3 yrs n=8
- Intermediate Progression
 - $>$ stage 2 at 3yrs $<$ stage 6 at 5yrs n=8

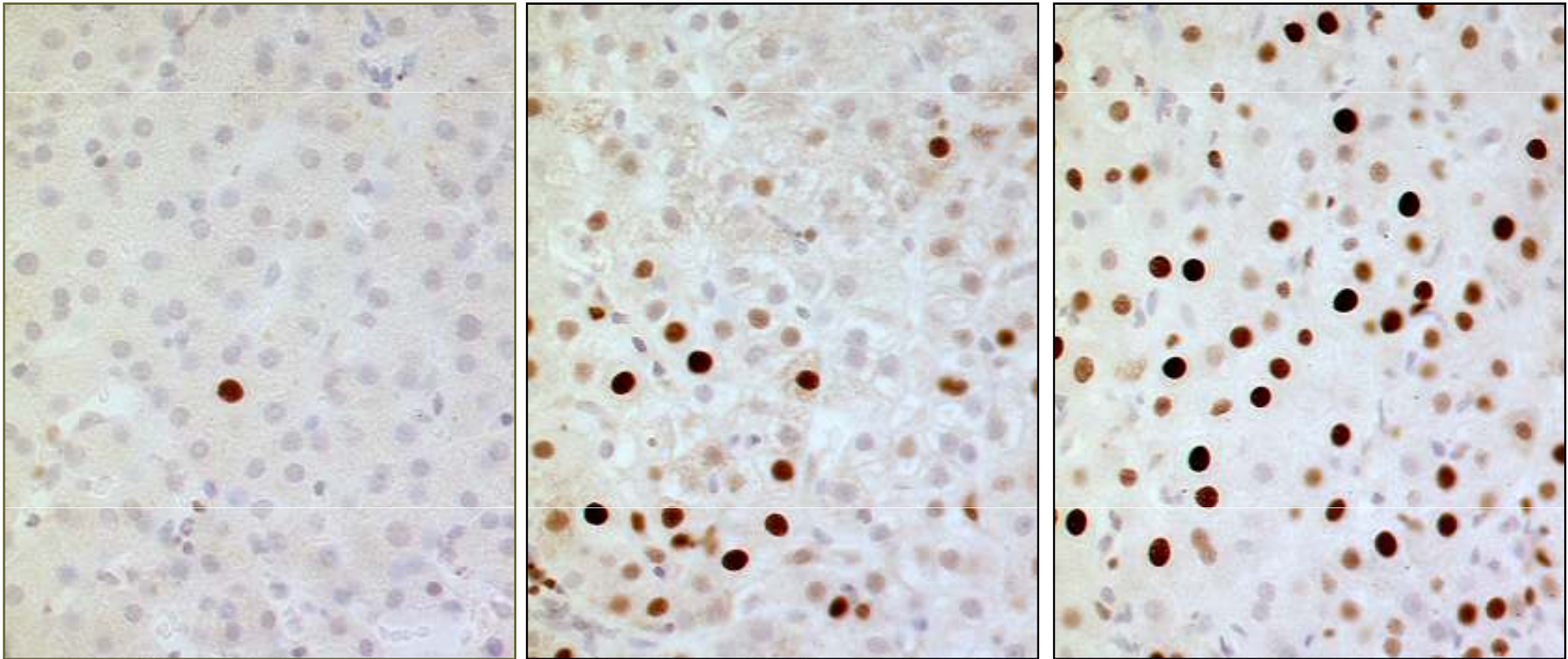
IHC

- First biopsy available after biochemical recurrence
- Labelling index of positive within the total
- Two observers, ~ 1000 cells; now semi-automated of whole biopsy
- Wide range of times; NP av 91d, RP 73d, IP 274

Histology of Biopsies

Group	NP	IP	RP	p value
Fat (0-3)	0 (0-1)	0 (0-2)	0 (0-1)	0.78
Confluent (0-6)	0 (0)	0.5 (0-2)	0 (0-3)	0.13
Interface (0-4)	2 (0-2)	1 (0-2)	1.5 (0-3)	0.66
Lobular (0-4)	2 (1-2)	2 (1-4)	3 (2-4)	0.026
Portal (0-4)	2 (1-2)	1.5 (1-3)	2 (1-4)	0.85
HAI (0-18)	6 (2-6)	5 (2-11)	6.5 (3-13)	0.47
Fibrosis (0-6)	1 (0-2)	1 (0-3)	2 (1-5)	0.3

MCM2 expression in early liver biopsies following OLT for HCV cirrhosis

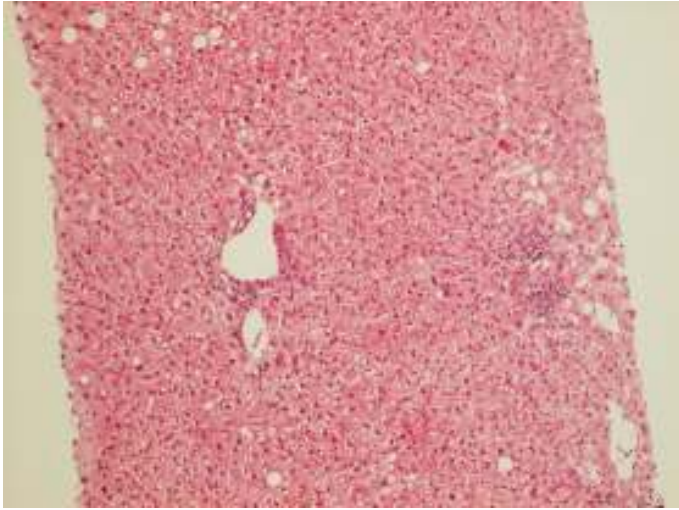


Non-progressor

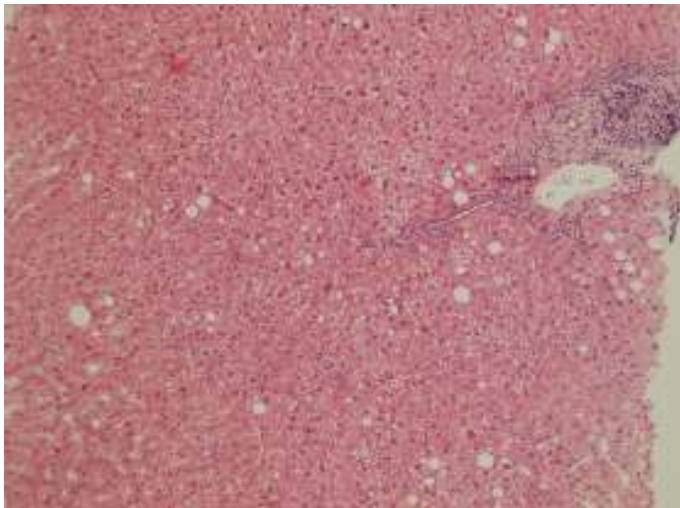
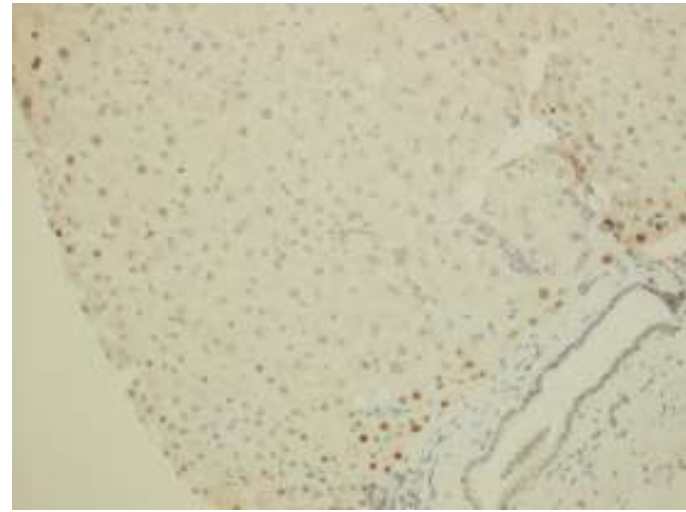
Intermediate
progressor

Rapid progressor

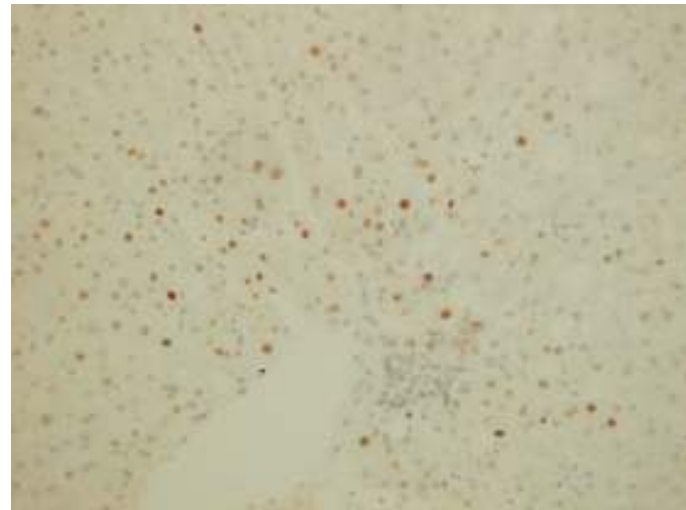
Non-Progressor –MCM2 staining



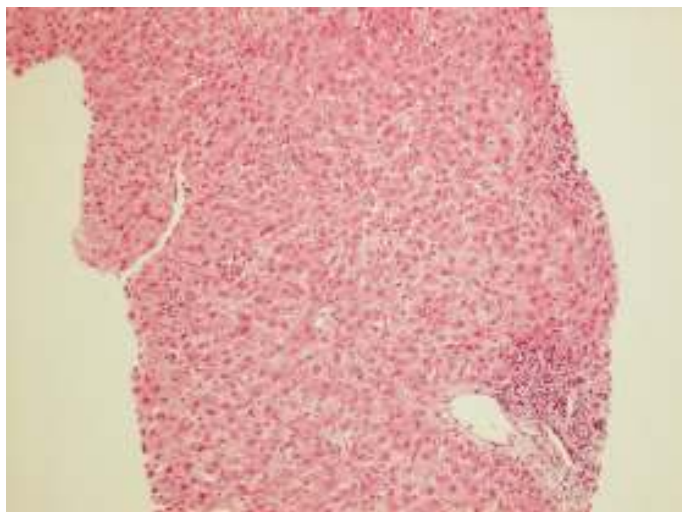
8
months



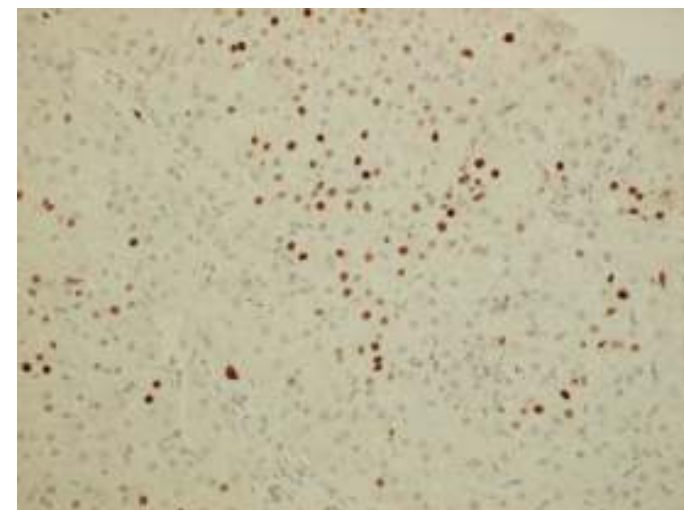
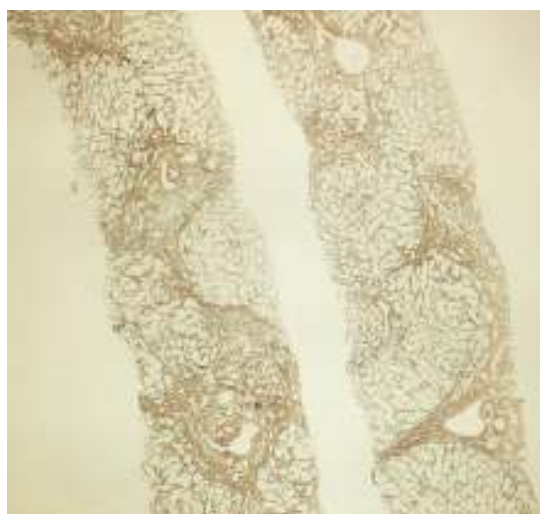
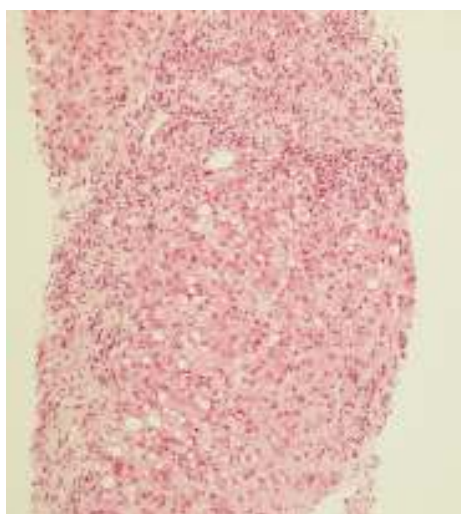
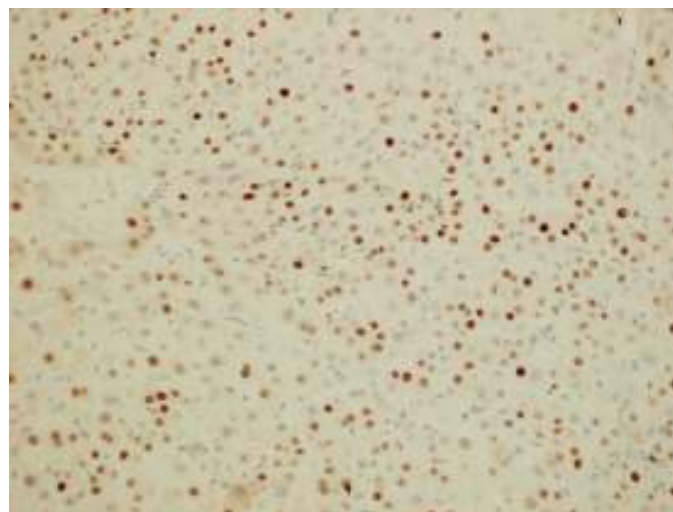
5
years



Rapid Progressor – MCM2 staining

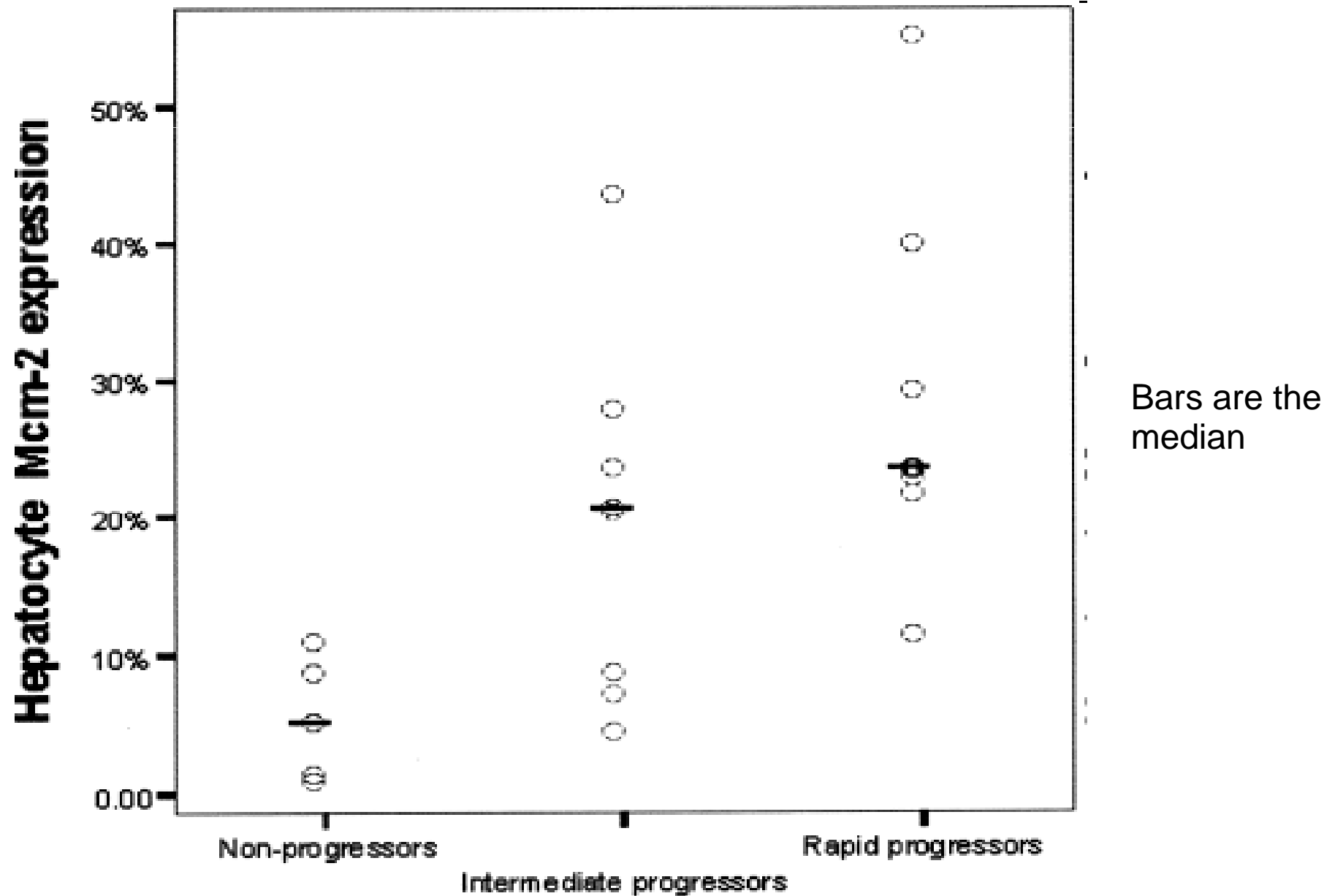


5
months



20 months

MCM2 labelling index in different progression groups



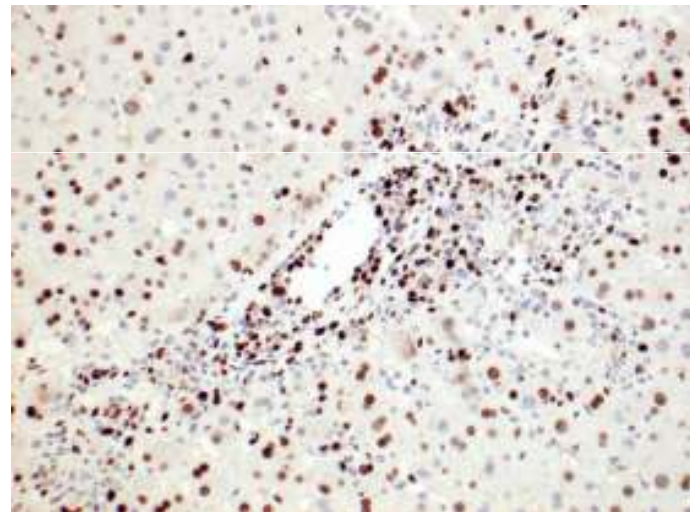
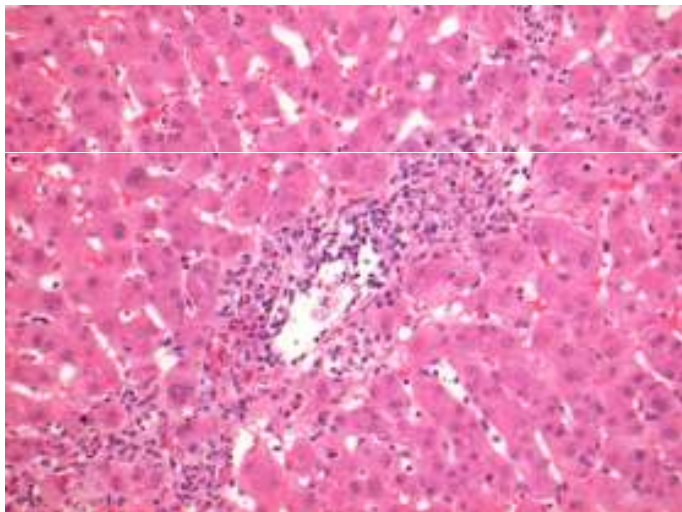
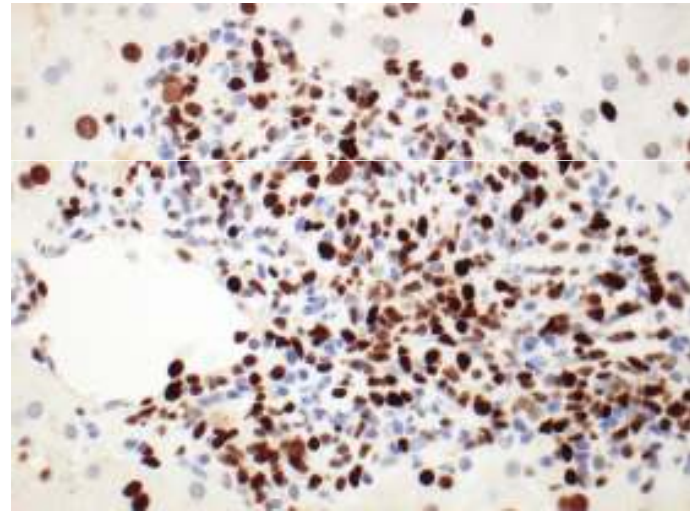
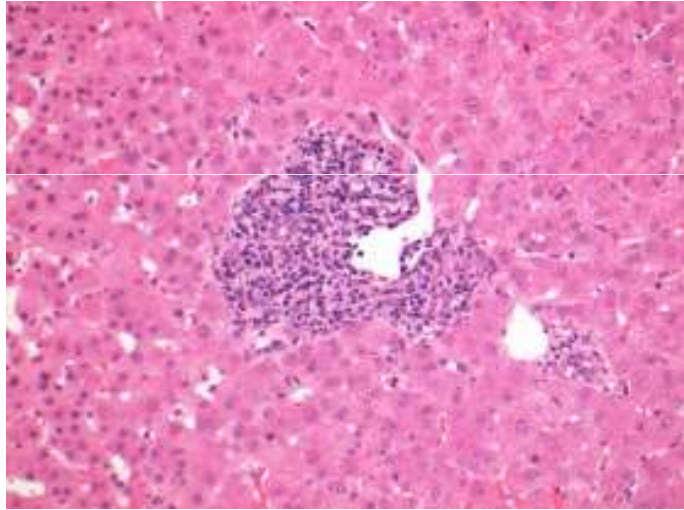
Immunosuppression

- All had initial triple therapy
 - Cyc or tacro + azathioprine + prednisolone
- Prednisolone tapered to end at 3 months; Aza stopped at 6 months
- No difference between cyclosporin and tacrolimus in 3 groups
- 6 (29%) had x1 ACR; all R₂ x3 iv methyl pred
 - All responded

HCV versus/and/or ACR

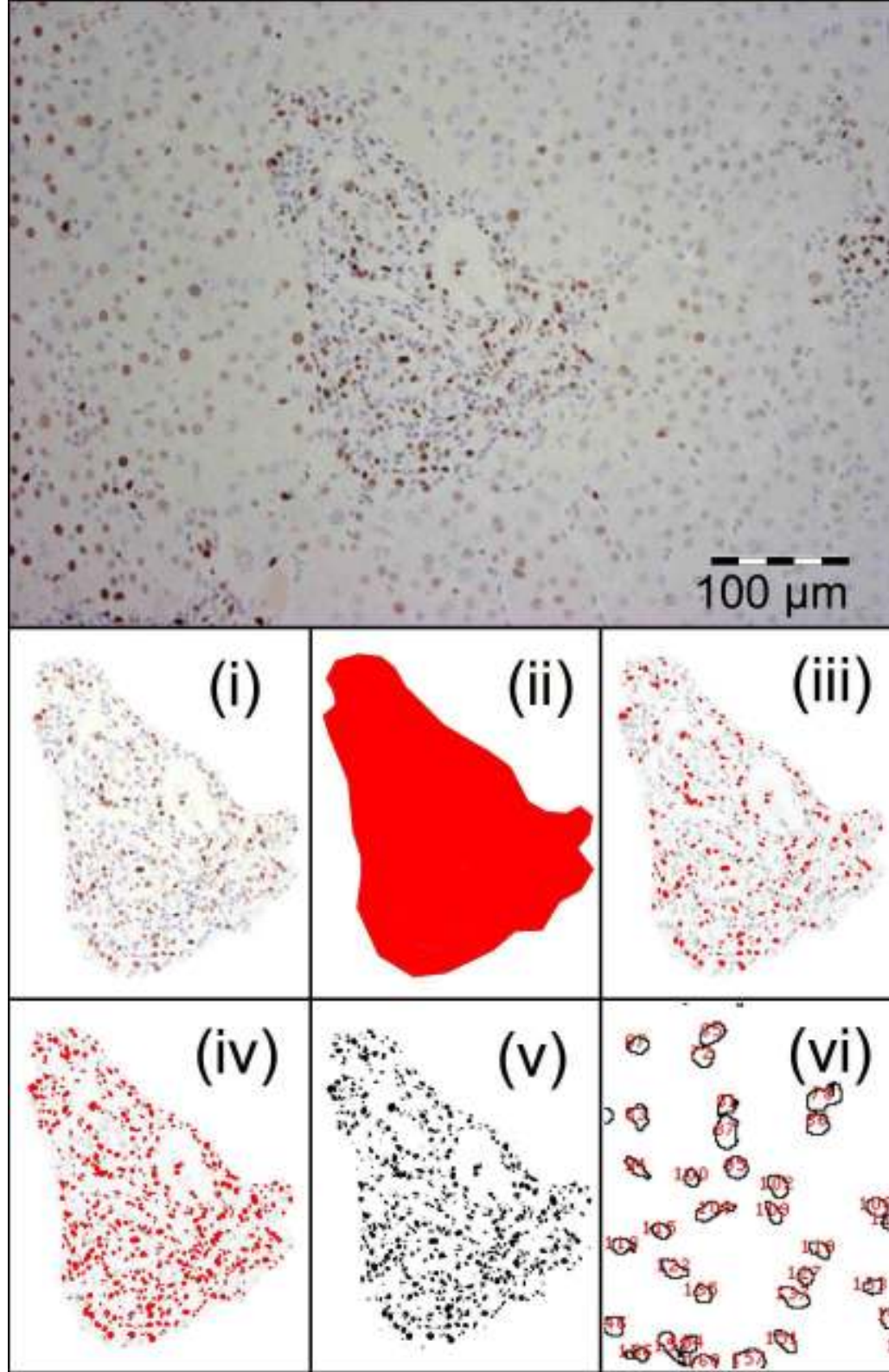
- Immunostaining for Mcm-2 of portal tracts *Unitt Liver Transpl 2009; 15: 306-312*
- 99 liver biopsies
 - 31 patients with HCV graft infection,
 - 22 patients with ACR
 - 11 patients with HCV infection and unexplained graft dysfunction
- Semi-automated counting per PT and per mm² of PT

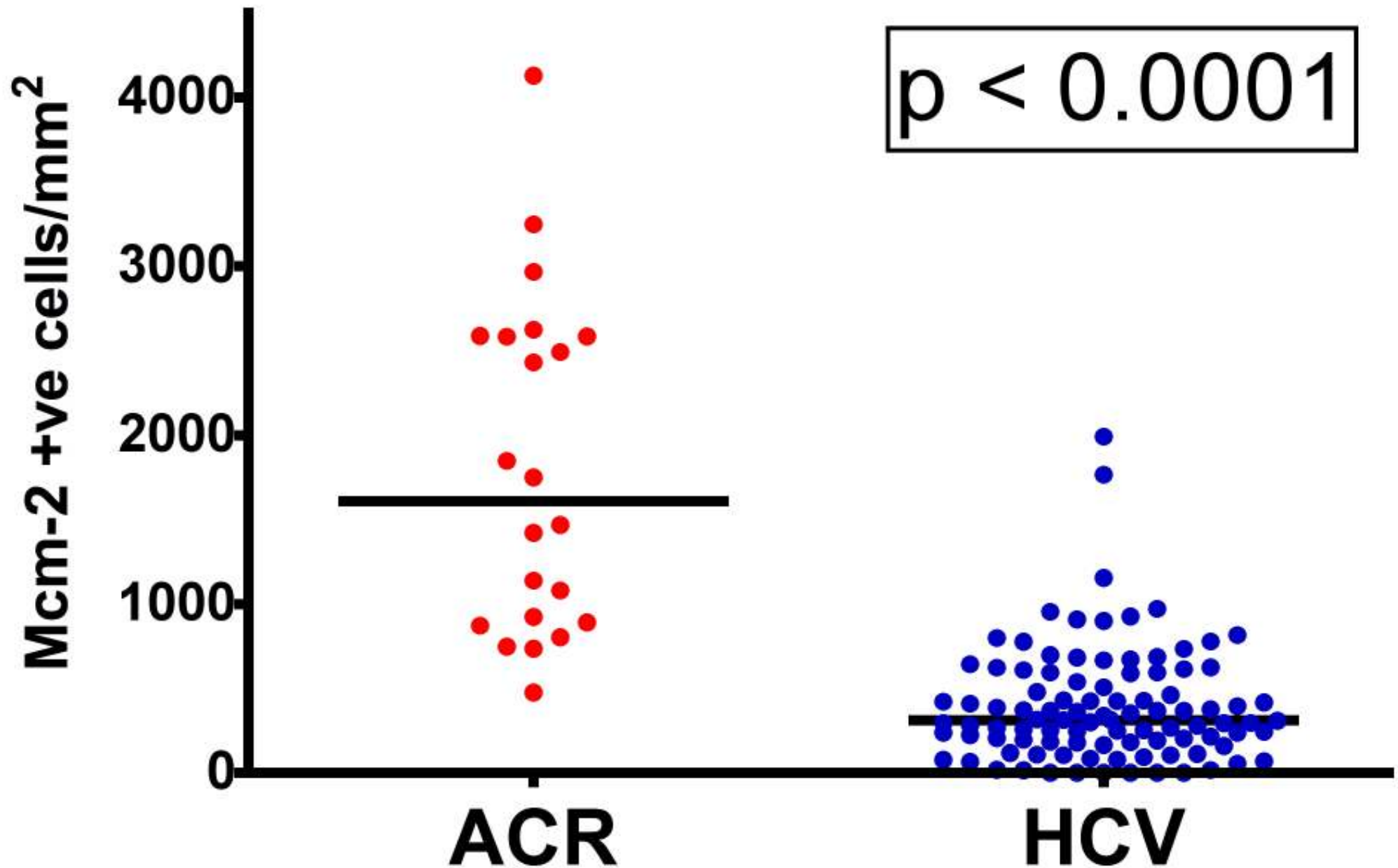
Typical MCM2 staining in ACR – non HCV patient



ImageJ software,
NIH

- I. Cut out of PT, subtract background noise
- II. Transfer into B&W – area of PT
- III. Set threshold, identify positive cells
- IV. and all nuclei determined
- V. With set threshold mask and a watershed...ie operator dependant
- VI. Nuclear count of positive and negative cells



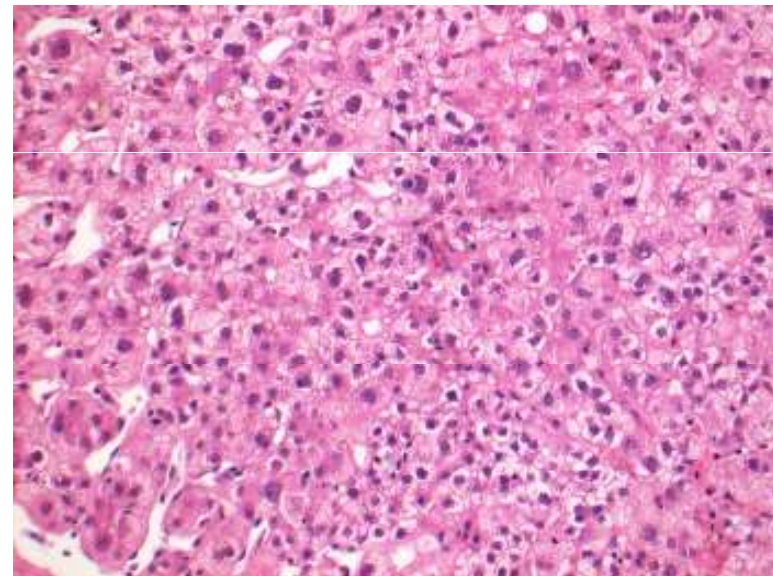
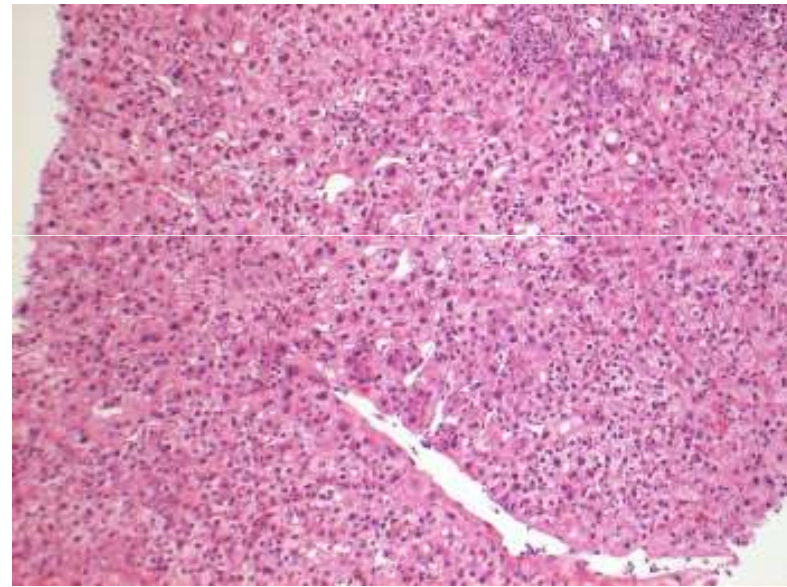
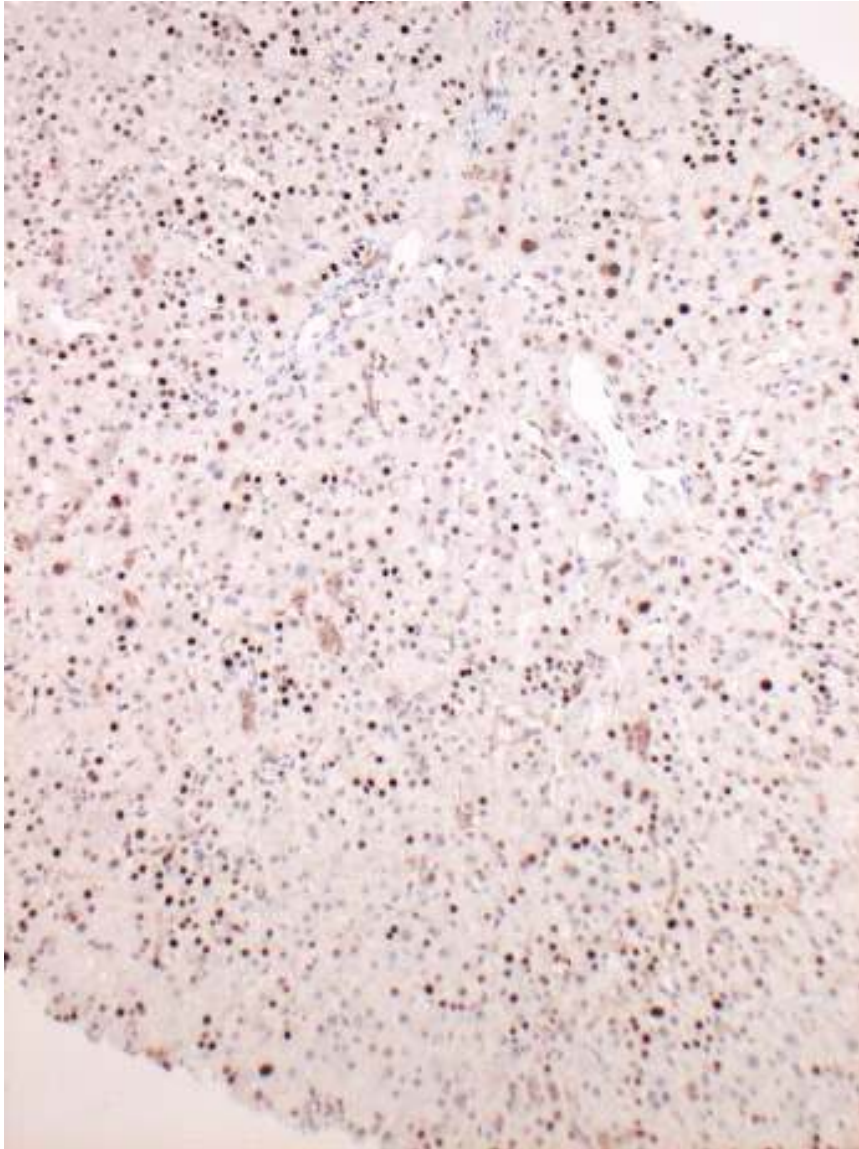


Cut off of 107 pos cells per portal tract, 1609 per mm 2, sensitivity of 81.8% and a specificity of 91.9%; positive predictive value of 66.67% and negative predictive value of 95.75%

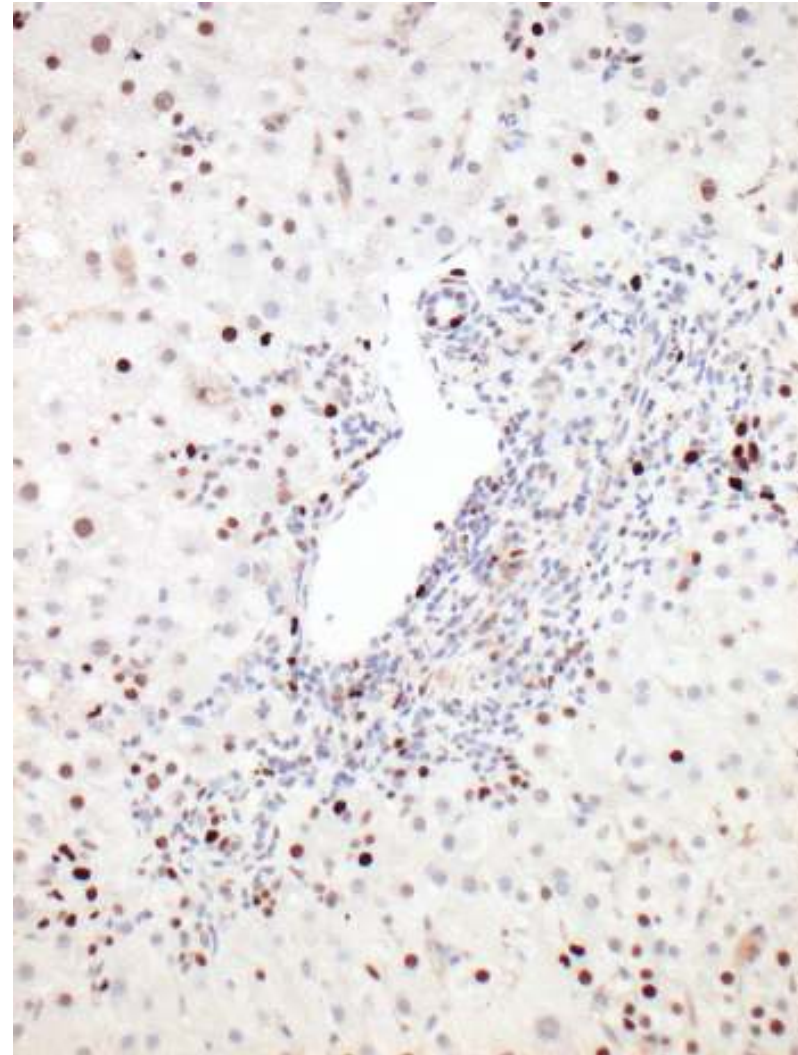
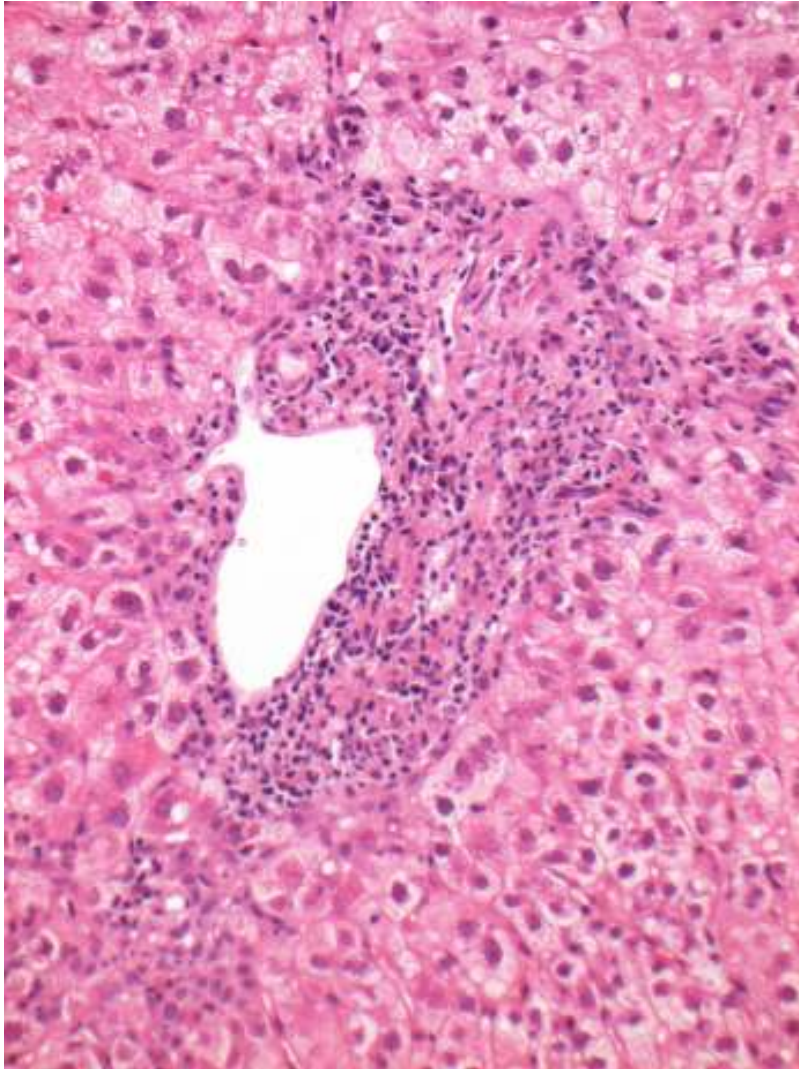
In difficult cases...

- 11 HCV-infected patients with uncertain diagnosis, review of all clinical and histological parameters, including improved LFTs post treatment for rejection
- 7 HCV thought graft infection alone, 4 superimposed corticosteroid-responsive ACR
- MCM2 staining separated these; 85 v 235 per PT...**but** range (17-121) v (120-471)

3 months in 3rd graft



Possible focal rejection?



Use of MCM2?

- Possibility of identifying the rapid progressors early, alter immunosuppression, consider other anti-viral strategies.
- Help understand pathogenesis; implications for cell cycle arrest.
- Adjunct in complex histology of HCV and rejection

Acknowledgements

- Aileen Marshall
- Will Gelson
- Esther Unitt
- Simon Rushbrook

- Nick Coleman
- Graeme Alexander